

Effect of 3-Dimensional Imaging Device on Polyp and Adenoma Detection During Colonoscopy: A Randomized Controlled Trial

Xiujing Sun, PhD^{1,*}, Qian Zhang, PhD^{1,*}, Shanshan Wu, PhD¹, Changqin Xu, PhD², Yang Zhang, MS¹, Xiaowen Hao, PhD¹, Ying Meng, PhD¹, Yue Jiao, PhD¹, Hongmei Li, PhD¹, Siying Zhu, PhD¹, Yanhua Zhou, PhD¹, Kuiliang Liu, PhD¹, Hongwei Xu, PhD², Shengtao Zhu, PhD¹ and Shutian Zhang, PhD¹

INTRODUCTION: To evaluate the effect of 3-dimensional (3D) imaging device on polyp and adenoma detection during colonoscopy.

METHODS: In a single-blind, randomized controlled trial, participants aged 18–70 years who underwent diagnostic or screening colonoscopy were consecutively enrolled between August 2019 and May 2022. Each participant was randomized in a 1:1 ratio to undergo either 2-dimensional (2D-3D) colonoscopy or 3D-2D colonoscopy through computer-generated random numbers. Primary outcome included polyp detection rate (PDR) and adenoma detection rate (ADR), defined as the proportion of individuals with at least 1 polyp or adenoma detected during colonoscopy. The primary analysis was intention-to-treat.

RESULTS: Of 1,196 participants recruited, 571 in 2D-3D group and 583 in 3D-2D group were finally included after excluding those who met the exclusion criteria. The PDR between 2D and 3D groups was separately 39.6% and 40.5% during phase 1 (odds ratio [OR] = 0.96, 95% confidence interval [CI]: 0.76–1.22, $P = 0.801$), whereas PDR was significantly higher in 3D group (27.7%) than that of 2D group (19.9%) during phase 2, with a 1.54-fold increase (1.17–2.02, $P = 0.002$). Similarly, the ADR during phase 1 between 2D (24.7%) and 3D (23.8%) groups was not significant (OR = 1.05, 0.80–1.37, $P = 0.788$), while ADR was significantly higher in 3D group (13.8%) than that of 2D group (9.9%) during phase 2, with a 1.45-fold increase (1.01–2.08, $P = 0.041$). Further subgroup analysis confirmed significantly higher PDR and ADR of 3D group during phase 2, particularly in midlevel and junior endoscopists.

DISCUSSION: The 3D imaging device could improve overall PDR and ADR during colonoscopy, particularly in midlevel and junior endoscopists. Trial number: ChiCTR1900025000.

KEYWORDS: three-dimensional imaging; adenoma; polyp; detection rate; colonoscopy

SUPPLEMENTARY MATERIAL accompanies this paper at <http://links.lww.com/AJG/C990>

Am J Gastroenterol 2023;00:1–9. <https://doi.org/10.14309/ajg.0000000000002396>

INTRODUCTION

As one of the leading causes of cancer-related death, colorectal cancer (CRC) is a pressing target for population screening worldwide (1). Colonoscopy has been considered as the gold standard for screening CRC, which has been shown to effectively reduce the incidence and mortality of CRC using the detection and removal of adenomas and polyps (2,3). Previous evidence indicated that per 1% increase of adenoma detection rate (ADR)

was associated with 3% decrease of incident CRC (4). However, missed polyps or adenomas remain a significant problem during colonoscopy. Recent studies demonstrated approximately 27% of polyps and 9% of advanced adenomas missed, particularly for small and flat lesions (5,6). In addition to inspection time and bowel preparation, size and morphology of polyp/adenoma lesions as well as endoscopist experience are all critical factors contributing to these unrecognized polyps or adenomas (4,7,8).

¹Department of Gastroenterology, Beijing Friendship Hospital, Capital Medical University, National Clinical Research Center for Digestive Disease, Beijing Digestive Disease Center, Beijing Key Laboratory for Precancerous Lesion of Digestive Disease, Beijing, China; ²Department of Gastroenterology, Shandong Provincial Hospital affiliated to Shandong First Medical University, Jinan, Shandong, China. Correspondence: Hongwei Xu, PhD. E-mail: xu_hong_wei@sina.com. Shengtao Zhu, PhD. Email: zhushengtao@ccmu.edu.cn. Shutian Zhang, PhD. E-mail: zhangshutian@ccmu.edu.cn.

*Xiujing Sun and Qian Zhang contributed equally for this study.

Received March 28, 2023; accepted June 13, 2023; published online August 7, 2023

A good visualization is essential to increase the detection rate of polyps and adenomas. The current standard technique of endoscopic visualization is using a 2-dimensional (2D) imaging on the screen. A recent development technique of 3-dimensional (3D) endoscopes provides a 3D imaging, which theoretically achieves additional realistic information in depth, anatomical details as well as orientation of polyps during the colonoscopy procedure.

To address this important issue, we developed a simple, feasible, and cost-effective 3D imaging device to assist colonoscopy procedure, to improve the detection rate of polyps and adenomas. Therefore, the aim of this study was to investigate whether the 3D imaging device can increase the detection rate of polyps and adenomas than conventional 2D colonoscopy in real clinical practice. In addition, we also aimed to assess the efficacy of 3D device in detection of small and flat polyps as well as in endoscopists of different levels and experiences.

METHODS

Three-dimensional imaging device

The 3D imaging device used in this trial was postmarketing (Type: 3DVS-S100A, Suzhou Scivita Medical Technology). Simply, the image processing device synthesizes the output image signal and converts it into a 3D signal displayed on the monitor, thereby achieving synchronous and real-time conversion of 2D endoscopic images into 3D images (Figure 1). The operator needs to wear 3D glasses to observe 3D images.

The detailed principle of monocular 3D imaging device was as follows (see Supplementary Figure S1, <http://links.lww.com/AJG/C990>). Based on the single-lens image, the perspective projection operation is used to generate the initial binocular image. After performing color gamut conversion, image concatenation, signal convolution, and network reconstruction, the resolution of binocular images would be enhanced. Subsequently, grayscale depth maps would be generated using the process of Sobel edge filtering, gradient detection, and depth extraction. Finally, based on the virtual reality theory, the 3D image would be reconstructed by combining the aforementioned grayscale depth map, vergence angle, and equivalent disparity.

Study design and participants

This was a multicenter, cross-over randomized controlled trial. The study protocol was approved by the Medical Ethics Committee of Beijing Friendship Hospital, Capital Medical University (approval number 2019-P2-143-01), and the institutional review boards at each participating center and was registered at Chinese Clinical Trial Registry (ChiCTR1900025000). Written informed

consent was obtained from each participant before randomization. The study was conducted in accordance with protocol and principles of the Declaration of Helsinki. All authors had access to the study data and reviewed and approved the final manuscript.

Participants aged 18–70 years who underwent a diagnostic or screening colonoscopy were consecutively enrolled between August 2019 and May 2022. Participants with history of inflammatory bowel disease, CRC, colorectal resection, or Peutz-Jeghers syndrome and a contradiction for biopsy were excluded. Those participants with severe cardiopulmonary insufficiency, mental illness, or poor bowel preparation who could not cooperate with the colonoscopy procedure were also excluded.

Randomization and masking

All eligible participants were randomized in a 1:1 ratio to undergo either 2D-3D colonoscopy (first examined with 2D colonoscopy, followed by a second inspection with 3D colonoscopy) or 3D-2D colonoscopy (first examined with 3D colonoscopy, followed by a second inspection with 2D colonoscopy). We used computer-generated random numbers in block sizes of 6 using the Proc Plan procedure of the SAS software version 9.4. Participants' enrollment and group assignment were performed independently by the study team members of each center. Group assignments were contained in ordered, sealed, and opaque envelopes. Participants were unaware of the group assignment, whereas endoscopists were not blinded to group assignment. Polyp specimens were assessed by pathologists who were masking of the group allocation.

Procedures and data collection

All participants received a 3-day low-fiber diet before colonoscopy and underwent routine bowel preparation consisting of 3 L of polyethylene glycol, given in split doses according to the study protocol. Bowel preparation quality was assessed by the Boston Bowel Preparation Scale (BBPS), with adequate bowel preparation being defined as BBPS score ≥ 6 and any segmental BBPS score ≥ 2 (9). Colonoscopies were conducted with high-definition colonoscopes (Olympus CF-Q260, CF-Q290) and high-definition monitors. Senior ($\geq 10,000$ colonoscopies), midlevel (between 5,000 and 10,000 colonoscopies), and junior ($\leq 5,000$ colonoscopies) endoscopists participated in this study. Because our design was a tandem colonoscopy trial, every participant experienced twice insertions and twice withdrawals of colonoscopes. For those in the 2D-3D group, participants first experienced insertion with 2D and withdrawal with 2D (phase 1), then experienced insertion with 2D and withdrawal with 3D (phase 2). By contrast, for those in the 3D-2D group, participants

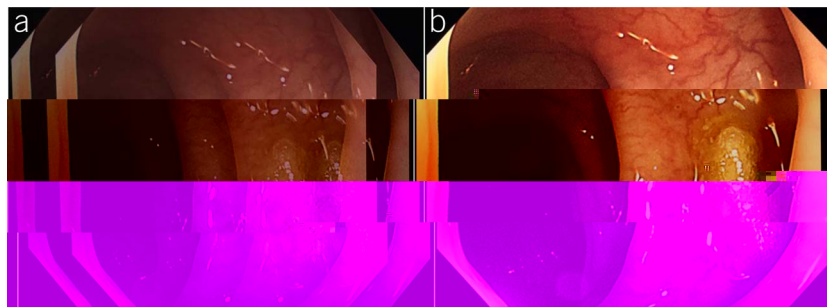


Figure 1. The synchronous and real-time conversion of 2-Dimensional endoscopic images into 3-Dimensional images.

Downloaded from <https://ajg.sagepub.com/> by [IP: 192.168.1.1] on 09/18/2023

first experienced insertion with 2D and withdrawal with 3D (phase 1), then experienced insertion with 2D and withdrawal with 2D (phase 2). During each phase of both groups, the endoscopists were required to conduct cold forceps biopsy of the lesion with the assistance of nurses for histological analysis whenever a polyp was detected. The polyps' location, size, and morphological features according to the Paris classification were also recorded accordingly.

Baseline demographic and clinical characteristics were obtained from participants before colonoscopy, including age, sex, body mass index, family history of CRC and adenoma, /C,an(seiidit)-268.9(C(diab5(T]TJTD[(lesion)-508.rom)-123.1(pa1.ona7(p49(C)-2cat3.6(ea7(p49(Ct-2cat38ic

total of 1,192 patients were enrolled and randomized, of whom 591 and 601 patients were assigned to the 2D-3D group and the 3D-2D group, respectively. After excluding patients with failed colonoscopy procedure or meeting other exclusion criteria, 571 patients in the 2D-3D group and 583 patients in the 3D-2D group were included in the intention-to-treat analysis (Figure 2). Baseline characteristics were similar between the 2 groups (mean age 52.3 years, male proportion 44.4%, Table 1). Of which, 529 (45.8%) underwent colonoscopy for screening. There was 93.1% of patients with adequate bowel preparation. Regarding the experience of the endoscopist, 647 (56.1%), 216 (18.7%), and 291 (25.2%) patients underwent colonoscopy by junior, midlevel, and senior endoscopists, respectively. The first and second withdrawal times including biopsy were 7.26 and 6.82 minutes, respectively. A total of 1,047 biopsies were performed, with 537 and 510 biopsies in the 2D-3D group and the 3D-2D group, respectively. Overall, a total of 4 participants (0.3%) experienced bleeding during the procedure, while no other complications of the procedure were reported.

Polyp characteristics and detection/miss rate

Overall, 1,047 polyps were identified, with 544 (52.0%) adenomas, 2 (0.2%) sessile serrated adenomas/polyps, and 3 (0.3%) carcinomas. The polyps were generally small in size (mean size 5.0 [SD: 6.6] mm), with most (79.5%) less than 5.0 mm. Regarding morphological features, most polyps (69.0%) were flat, followed by sessile (26.9%). No statistically significant difference was detected between 2 groups regarding polyps' characteristics (Table 2, see Supplementary Table S1, <http://links.lww.com/AJG/C990>).

The PDRs between 2D and 3D groups during phase 1 were 39.6% and 40.5%, respectively (OR = 0.96, 95% confidence interval [CI]: 0.76–1.22, $P = 0.801$). Meanwhile, the PDR was significantly higher in the 3D group (27.7%) than that of the 2D group (19.9%) during phase 2, with a 1.54-fold increase (95% CI: 1.17–2.02, $P = 0.002$) in polyp detection (Table 3). Regarding the miss rate (Figure 3), a significant lower polyp miss rate was detected in the 3D group (28.8%) compared with that of the 2D group (39.1%).

Adenoma characteristics and detection/miss rate

A total of 544 adenomas were detected, with 46 (4.4%) advanced adenomas. The mean size of adenomas was 5.3 (SD: 4.7) mm, with majority (72.4%) less than 5.0 mm. As for morphological features, most adenomas (55.7%) were flat, followed by sessile (38.2%). No statistically significant difference was detected between the 2 groups regarding adenomas' characteristics (Table 2).

Despite ADRs during phase 1 between 2D (24.7%) and 3D (23.8%) groups were not significant (OR = 1.05, 95% CI: 0.80–1.37, $P = 0.788$), the ADR was significantly higher in the 3D group (13.8%) than that of the 2D group (9.9%) during phase 2, with a 1.45-fold increase (95% CI: 1.01–2.08, $P = 0.041$) in adenoma detection (Table 3). Regarding the miss rate (Figure 3), a lower adenoma miss rate was achieved in the 3D group (25.4%) vs 2D group (31.8%) despite nonsignificant ($P = 0.099$).

Subgroup analysis

As shown in Table 3, subgroup analysis by experience of endoscopists indicated the significantly higher PDR of the 3D group during phase 2, particularly in midlevel and junior endoscopists, with a 1.94-fold (1.03–3.63, $P = 0.040$) and 1.55-fold (1.07–2.24, $P = 0.021$) increase in polyp detection, respectively. The evidently

higher ADR of the 3D group during phase 2 was also observed in junior endoscopists compared with the 2D group (OR = 1.74, 1.08–2.80, $P = 0.021$). Moreover, a significantly lower miss rate of polyps ($P = 0.002$) and adenomas ($P = 0.025$) were detected in the 3D group compared with that of the 2D group (Figure 3).

Furthermore, a lower miss rate by 3D (30.8%) was particularly evident in polyps with small size (0–5 mm), in comparison with conventional 2D (42.8%, $P < 0.001$, Figure 4). Similarly, consistent subgroup findings were observed, with a lower miss rate of flat polyps in 3D (35.9%) compared with that of 2D group (47.5%, $P = 0.002$, see Supplementary Figure S2, <http://links.lww.com/AJG/C990>).

Sensitivity analysis

The results of sensitivity analysis in participants who were with adequate bowel preparation or who aged 45 years or older were all consistent with principal findings, either in PDR, ADR, or miss rate of polyps and adenomas (see Supplementary Table S2–S3, Figure S3, <http://links.lww.com/AJG/C990>).

DISCUSSION

In this multicenter randomized controlled trial, we demonstrated that the 3D imaging device could significantly improve both the overall PDR and ADR during colonoscopy by a 1.54-fold and 1.45-fold increase, respectively. Meanwhile, PDR and ADR were evidently improved particularly in midlevel and junior endoscopists, with a 1.55–1.94-fold increase in polyp or adenoma detection. Furthermore, the 3D imaging device also showed excellent performance in detecting small and flat lesions during colonoscopy. These findings are of considerable value given the rapidly growing burden of CRC worldwide and the urgent need for addressing unrecognized polyps/adenomas within the visual field of the colonoscopy (1,5–7).

Although colonoscopy has been considered as the gold standard for screening CRC because of its high sensitivity, missed polyps or adenomas is still a major issue (2–7). It was estimated that approximately 9%–27% of polyps/adenomas were overlooked during the conventional 2D colonoscopy procedure (5,6). In this circumstance, the 3D imaging technology was introduced to improve the PDR and ADR by highlighting the morphological characteristics of lesions, thereby providing assistance for lesion identification (10–14). Prior evidence indicated that 3D imaging devices could not only increase the contrast between lesions and adjacent mucosa in real time but also did not prolong the operation time (14). Consistently, no statistically significant difference in the withdrawal time between the 2 groups was detected in our study, indicating the simple operation of 3D imaging devices. Meanwhile, the 3D imaging devices can be used in conjunction with various types of endoscopic image processing devices, thereby may have potential applications in routine clinical practice.

In addition to inspection time and bowel preparation, size and morphology of polyp/adenoma lesions as well as endoscopist experience are all critical factors contributing to missed polyps or adenomas (4,7,8). It has been reported that as the diameter of the lesion increases, the missed rate becomes lower (15). Approximately 20%–30% of lesions below 5 mm were missed during the conventional 2D colonoscopy (16). Similarly, flat lesions were more likely to be missed than elevated lesions, particularly in proximal colon (17). In our study, an evident increase in the detection of small and flat lesions was observed in the 3D group

Downloaded from <https://ajg.sagepub.com/> by BMDM5e9PHKav1zEoum1tQINMa+kjLHEZgbsH04XMI0hCwCXC1AW
 on 09/18/2023

Table 2. Characteristics of polyps and adenomas

Characteristic	Overall	2D-3D group	3D-2D group	P value
No. of polyps	1,047	537	510	
Pathology				0.743
Carcinoma	3 (0.3)	1 (0.2)	2 (0.4)	
Sessile serrated adenoma/polyp (SSAP)	2 (0.2)	0 (0.0)	2 (0.4)	
Advanced adenoma	46 (4.4)	22 (4.1)	24 (4.7)	
Other adenoma	498 (47.6)	258 (48.0)	240 (47.1)	
Benign lesions (hyperplastic and inflammatory)	493 (47.1)	253 (47.1)	240 (47.1)	
Normal colon mucosa	5 (0.5)	3 (0.6)	2 (0.4)	
Polyp location				0.878
Caecum	71 (6.8)	33 (6.2)	38 (7.5)	
Ascending	134 (12.8)	66 (12.3)	68 (13.3)	
Transverse	275 (26.3)	144 (26.8)	131 (25.7)	
Descending	132 (12.6)	70 (13.0)	62 (12.2)	
Sigmoid	229 (21.9)	122 (22.7)	107 (21.0)	
Rectum	206 (19.7)	102 (19.0)	104 (20.4)	
Polyp shape				0.200
Pedunculated	36 (3.4)	15 (2.8)	21 (4.1)	
Sessile	282 (26.9)	133 (24.8)	149 (29.2)	
Flat	722 (69.0)	385 (71.7)	337 (66.1)	
LST	7 (0.7)	4 (0.7)	3 (0.6)	
Polyp size (mm) ^a	5.0 ± 6.6	5.0 ± 5.9	4.9 ± 7.3	0.856
Polyp size category				0.103
0–5 mm	832 (79.5)	439 (81.8)	393 (77.1)	
6–10 mm	169 (16.1)	74 (13.8)	95 (18.6)	
>10 mm	46 (4.4)	24 (4.5)	22 (4.3)	
Adenoma location				0.731
Caecum	32 (5.9)	13 (4.6)	19 (7.2)	
Ascending	82 (15.1)	44 (15.7)	38 (14.4)	
Transverse	169 (31.1)	90 (32.1)	79 (29.9)	
Descending	92 (16.9)	50 (17.9)	42 (15.9)	
Sigmoid	119 (21.9)	57 (20.4)	62 (23.5)	
Rectum	50 (9.2)	26 (9.3)	24 (9.1)	
Adenoma shape				0.121
Pedunculated	29 (5.3)	13 (4.6)	16 (6.1)	
Sessile	208 (38.2)	96 (34.3)	112 (42.4)	
Flat	303 (55.7)	168 (60.0)	135 (51.1)	
LST	4 (0.7)	3 (1.1)	1 (0.4)	
Adenoma size (mm) ^a	5.3 ± 4.7	5.3 ± 5.2	5.4 ± 4.2	0.869
Adenoma size category				0.433
0–5 mm	394 (72.4)	209 (74.6)	185 (70.1)	
6–10 mm	127 (23.4)	59 (21.1)	68 (25.8)	
>10 mm	23 (4.2)	12 (4.3)	11 (4.2)	

Numbers are n (%) unless otherwise stated.

^aDisplayed as mean ± SD.

Table 3. Polyp and adenoma detection

Detection rate Total (N = 1,154)	2D-3D group N = 571	3D-2D group N = 583	OR (95% CI)	P value
PDR				
Phase 1	226 (39.6)	236 (40.5)	0.96 (0.76–1.22)	0.801
Phase 2	158 (27.7)	116 (19.9)	1.54 (1.17–2.02)	0.002
ADR				
Phase 1	141 (24.7)	139 (23.8)	1.05 (0.80–1.37)	0.788
Phase 2	79 (13.8)	58 (9.9)	1.45 (1.01–2.08)	0.041
Subgroup analysis by endoscopist experience				
Senior (N = 291)		N = 141		N = 150
PDR				
Phase 1	62 (44.0)	60 (40.0)	1.17 (0.74–1.87)	0.493
Phase 2	39 (27.7)	34 (22.7)	1.30 (0.77–2.21)	0.326
ADR				
Phase 1	44 (31.2)	33 (22.0)	1.61 (0.95–2.71)	0.075
Phase 2	16 (11.3)	17 (11.3)	1.00 (0.49–2.05)	0.997
Midlevel (N = 216)		N = 108		N = 108
PDR				
Phase 1	46 (42.6)	45 (41.7)	1.04 (0.61–1.78)	0.890
Phase 2	33 (30.6)	20 (18.5)	1.94 (1.03–3.63)	0.040
ADR				
Phase 1	25 (23.1)	25 (23.1)	1.00 (0.53–1.87)	1.000
Phase 2	13 (12.0)	10 (9.3)	1.34 (0.57–3.14)	0.508
Junior (N = 647)		N = 322		N = 325
PDR				
Phase 1	118 (36.6)	131 (40.3)	0.86 (0.62–1.18)	0.339
Phase 2	86 (26.7)	62 (19.1)	1.55 (1.07–2.24)	0.021
ADR				
Phase 1	72 (21.6)	81 (24.4)	0.87 (0.60–1.24)	0.443
Phase 2	50 (15.0)	31 (9.3)	1.74 (1.08–2.80)	0.021

2D, 2-Dimensional; 3D, 3-Dimensional; ADR, adenoma detection rate; CI, confidence interval; OR, odds ratio; PDR, polyp detection rate.

compared with conventional 2D colonoscopy, suggesting that 3D imaging may have better depth recognition capability than 2D imaging. However, whether these increase in small and diminutive lesions' detection could translate into a decrease risk of interval CRC, thereby achieving a better CRC prevention in the long term, is still unclear to date. Further long-term studies are warranted to address this issue, which is the main goal of screening colonoscopy.

Owing to the lack of experience, it can be challenging for junior endoscopists to screen and diagnose the small and flat lesions in colonoscopy, leading to missed polyp and adenoma detection. Previous studies indicated that senior endoscopists had a much higher detection rate than junior endoscopists (18). Our findings demonstrated a significant improvement of PDR and ADR in midlevel and junior endoscopists, rather than in senior endoscopists. Hence, the application of the 3D imaging device might be more helpful for the beginner endoscopists in clinical practice, which could increase the detection rate and quality of colonoscopy.

The major strength of this study is to highlight the efficacy of the 3D imaging device on detecting colorectal polyps/adenomas during colonoscopy for the first time, based on the well-designed randomized controlled trial. The cross-over and tandem design including 2 phases allowed the calculation of miss rate for polyps and adenomas in addition to the detection rate. The large sample size from multiple research centers allowed substantial subgroup analysis by endoscopist experience, polyp/adenoma size, and morphological classifications available with sufficient statistical power, further confirming the excellent performance of 3D imaging device on identifying small flat lesions. In addition, rigorous sensitivity analysis by accounting for bowel preparation status was conducted, verifying robustness of principal results.

Several limitations also need to be considered. First, it is impossible to conduct the double-blind randomized trial because of the 3D/2D colonoscopy procedure. Hence, the endoscopists could not be blinded during the colonoscopy procedure, which

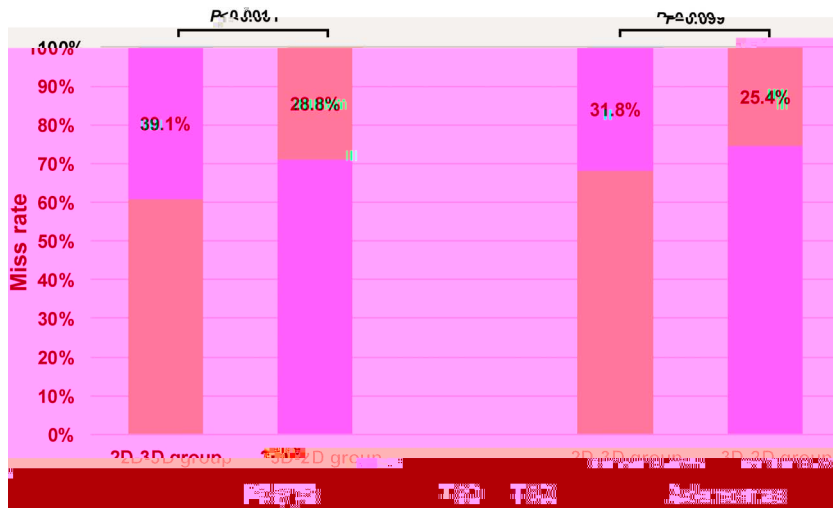


Figure 3. Miss rate of polyps and adenomas for each group (2D-3D and 3D-2D). 2D, 2-Dimensional; 3D, 3-Dimensional.

may lead to the potential measurement error (i.e., favoring 3D view) in the detection of polyps or adenomas. However, the withdrawal time during the 2 phases, either including biopsy time or excluding biopsy time, was similar between the 2 groups (all *P* values > 0.05), suggesting the similar observation attentiveness of endoscopists from the 2 groups. Second, participants who underwent either diagnostic or screening colonoscopy were all included in our study with a relatively lower detection rate of polyps and adenomas compared with those in western countries (2,19,20). Moreover, our study was only conducted in tertiary hospitals instead of general endoscopy unit. Thus, it is unclear whether our results can be generalized to other western populations or other general endoscopy units. However, individuals aged 45 years or older in our trial achieved a higher detection rate of polyps and adenomas, suggesting the relative low detection rate may be due to the fact of enrolling some participants younger than 45 years (see Supplementary Table S2, <http://links.lww.com/AJG/C990>). Future randomized trials in different populations

within diverse levels of health care institutions are warranted to confirm our findings. Third, the average of no polyp withdrawal time in the first phase was relatively shorter than the time recommended by the guidelines. Thus, it may lead to missed polyps or adenomas and further lower detection rate because of inadequate time of inspection. Fourth, because this trial was conducted only using the Olympus colonoscopy equipment, it is yet unclear whether the 3D imaging device can achieve similar excellent performance on colonoscopy equipment manufactured by other companies. Fifth, a 4-arm design (i.e., 2D-2D, 2D-3D, 3D-3D, 3D-2D) would be better compared with our current 2-arm design (i.e., 2D-3D, 3D-2D), allowing to examine the impact of the tandem approach. Finally, as a cross-over design, all participants experienced twice withdrawal phase with one 3D imaging device and another conventional 2D device. Thus, our study could not mimic the colonoscopy procedure in real clinical setting. Further parallel, pragmatic controlled trials are needed to validate the efficacy of 3D imaging device in routine clinical practice.




Figure 4. Subgroup analysis by endoscopist experience (a–c) and size (d–f) for miss rate of polyps and adenomas in each group (2D-3D and 3D-2D). (a) senior; (b) midlevel; (c) junior; (d) 0–5 mm; (e) 6–10 mm; (f) >10 mm. 2D, 2-Dimensional; 3D, 3-Dimensional.

Downloaded from <https://journals.lww.com/ajg> by BHDMSepHKav1zEum1tQIN4a+kjLhEZgbsH04XMM0hCwCk1A1AW
 on 09/18/2023

In summary, this randomized controlled trial showed that the 3D imaging device could improve overall PDR and ADR during colonoscopy, particularly in midlevel and junior endoscopists. Meanwhile, the 3D imaging device seemed helpful in detecting small and flat lesions during colonoscopy with lower miss rate. Considering the feasibility and excellent performance for polyps/adenomas' detection, the current 3D imaging device may potentially applicable in routine clinical practice for better detection of colorectal polyps or adenomas.

CONFLICTS OF INTEREST

Guarantors of the article: Shengtao Zhu, PhD and Shutian Zhang, PhD.

Specific author contributions: S.T.Zhang, X.J.S. and S.T.Zhu: designed the study. X.J.S., C.Q.X., H.W.X., Y.Z., X.W.H., Y.M., Y.J., H.M.L., S.Y.Z., Y.H.Z. and K.L.L.: enrolled the participants. X.J.S. and Q.Z.: drafted the manuscript. Q.Z. and S.S.W.: analyzed the data. S.S.W., Q.Z. and X.J.S.: revised the manuscript. S.S.W., X.J.S., Q.Z., S.T.Zhang, C.Q.X. and S.T.Zhu interpreted the results, incorporated comments for the co-authors and finalized the manuscript. All authors approved the final version of the paper.

Financial support: This work was funded by Beijing Science and Technology Project (No. Z191100006619082).

Potential competing interests: None to report.

Disclaimer: None of the funding organizations had any role in the design and conduct of the study; in the collection, management, and analysis of the data or in the preparation, review, and approval of the manuscript.

Study Highlights

WHAT IS KNOWN

- ✓ Colonoscopy has been considered as the gold standard for screening colorectal cancer. However, missed polyps or adenomas remain a significant problem during colonoscopy.
- ✓ Whether the 3D imaging device can increase the detection rate of polyps and adenomas than conventional 2D colonoscopy in real clinical practice is needed to be investigated.

WHAT IS NEW HERE

- ✓ In this randomized controlled trial, the 3D imaging device could improve overall PDR and ADR during colonoscopy, particularly in midlevel and junior endoscopists.
- ✓ Meanwhile, the 3D imaging device seemed helpful in detecting small and flat lesions during colonoscopy with lower miss rate.

REFERENCES

1. Sung H, Ferlay J, Siegel RL, et al. Global cancer statistics 2020: GLOBOCAN estimates of incidence and mortality worldwide for 36 cancers in 185 countries. *CA Cancer J Clin* 2021;71:209–49.
2. Brethauer M, Løberg M, Wieszczy P, et al. Effect of colonoscopy screening on risks of colorectal cancer and related death. *N Engl J Med* 2022;387(17):1547–56.
3. Davidson KW, Barry MJ, Mangione CM, et al. Screening for colorectal cancer: US preventive services task force recommendation statement. *JAMA* 2021;325:1965–77.
4. Corley DA, Jensen CD, Marks AR, et al. Adenoma detection rate and risk of colorectal cancer and death. *N Engl J Med* 2014;370:1298–306.
5. Zhao S, Wang S, Pan P, et al. Magnitude, risk factors, and factors associated with adenoma miss rate of tandem colonoscopy: A systematic review and meta-analysis. *Gastroenterology* 2019;156:1661–74.e11.
6. Ahn SB, Han DS, Bae JH, et al. The miss rate for colorectal adenoma determined by quality-adjusted, back-to-back colonoscopies. *Gut Liver* 2012;6:64–70.
7. le Clercq CM, Bouwens MW, Rondagh EJ, et al. Postcolonoscopy colorectal cancers are preventable: A population-based study. *Gut* 2014; 63:957–63.
8. Xu H, Tang RSY, Lam TYT, et al. Artificial intelligence-assisted colonoscopy for colorectal cancer screening: A multicenter randomized controlled trial. *Clin Gastroenterol Hepatol* 2023;21(2):337–46.e3.
9. Lai EJ, Calderwood AH, Doros G, et al. The Boston bowel preparation scale: A valid and reliable instrument for colonoscopy-oriented research. *Gastrointest Endosc* 2009;69:620–5.
10. Refai H, Koudsi B, Kudsil OY. Novel polyp detection technology for colonoscopy: 3D optical scanner. *Endosc Int Open* 2020;8(11):E1553–9.
11. Higuchi K, Kaise M, Noda H, et al. Three-dimensional flexible endoscopy enables more accurate endoscopic recognition and endoscopic submucosal dissection marking for superficial gastric neoplasia: A pilot study to compare two- and three-dimensional imaging. *Surg Endosc* 2021;35(11):6244–50.
12. Higuchi K, Kaise M, Noda H, et al. Three-dimensional visualization improves the endoscopic diagnosis of superficial gastric neoplasia. *BMC Gastroenterol* 2021;21(1):242.
13. Nomura K, Kikuchi D, Kaise M, et al. Comparison of 3D endoscopy and conventional 2D endoscopy in gastric endoscopic submucosal dissection: An ex vivo animal study. *Surg Endosc* 2019;33(12):4164–70.
14. Durr NJ, González G, Parot V. 3D imaging techniques for improved colonoscopy. *Expert Rev Med Devices* 2014;11(2):105–7.
15. Wang P, Liu X, Berzin TM, et al. Effect of a deep-learning computer-aided detection system on adenoma detection during colonoscopy (CADE-DB trial): A double-blind randomised study. *Lancet Gastroenterol Hepatol* 2020;5(4):343–51.
16. Pohl H, Robertson DJ. Colorectal cancers detected after colonoscopy frequently result from missed lesions. *Clin Gastroenterol Hepatol* 2010; 8(10):858–64.
17. Nomura K, Kaise M, Kikuchi D, et al. Recognition accuracy using 3D endoscopic images for superficial gastrointestinal cancer: A crossover study. *Gastroenterol Res Pract* 2016;2016:4561468.
18. Lu JH, Chen HX, Chen X, et al. Evaluation of the detection rate of high-grade gastric intraepithelial neoplasia using linked color imaging and white light imaging. *Exp Ther Med* 2023;25(3):107.
19. Aslanian HR, Shieh FK, Chan FW, et al. Nurse observation during colonoscopy increases polyp detection: A randomized prospective study. *Am J Gastroenterol* 2013;108:166–72.
20. Jia H, Pan Y, Guo X, et al. Water exchange method significantly improves adenoma detection rate: A multicenter, randomized controlled trial. *Am J Gastroenterol* 2017;112:568–76.